

SHORT REPORT

Eccentric training in Achilles tendinopathy: is it harmful to tendon microcirculation?

Karsten Knobloch

Br J Sports Med 2007;41:e2 (<http://www.bjsportmed.com/cgi/content/full/41/6/e2>). doi: 10.1136/bjsm.2006.030437

Background: Eccentric training has been shown to reduce pain and gain function in patients with chronic Achilles tendinopathy. However, currently no data are available regarding any potential adverse effects of an eccentric training intervention on Achilles tendon microcirculation.

Methods: 59 patients (49 (12) years; body mass index 27 (5); 49 mid-portion, 10 chronic insertional tendinopathy) with 64 symptomatic (54 mid-portion, 10 insertional) Achilles tendons were prospectively enrolled. Baseline tendon microcirculation at four distinct tendon positions from the insertion to the proximal mid-portion area was assessed using a laser Doppler system for capillary blood flow, tissue oxygen saturation and postcapillary venous filling pressure. A 12-week daily painful home-based eccentric training regimen was initiated (3×15 repetitions per tendon and day).

Results: Achilles tendon capillary blood flow was significantly reduced at the insertion (by 35%, $p=0.008$) and the distal mid-portion area (by 45%, $p=0.015$) at 2 mm and by 22% ($p=0.007$) and 13% ($p=0.122$) at 8 mm tissue depths, respectively. Achilles tendon oxygen saturation was not decreased after the 12-week eccentric training regimen throughout the insertion to the proximal mid-portion area (insertion 72 (13) vs 73 (10), proximal mid-portion 63 (13) vs 62 (11), both NS). Achilles tendon postcapillary venous filling pressures were significantly reduced at the insertion (51 (16) vs 41 (19), $p=0.001$) and the distal mid-portion (36 (13) vs 32 (12), $p=0.037$) at 2 mm and at the insertion at 8 mm (63 (19) vs 51 (13), $p=0.0001$). Pain was reduced from 5.4 (2.1) to 3.6 (2.4; $p=0.001$) in the mid-portion and from 6 (2.5) to 3.2 (2.7; $p=0.002$) in the insertional tendinopathy group. No Achilles tendon rupture or any interruption during the eccentric training was noted among the 59 patients.

Conclusion: Daily eccentric training for Achilles tendinopathy is a safe and easy measure, with beneficial effects on the microcirculatory tendon levels without any evident adverse effects in both mid-portion and insertional Achilles tendinopathy.

Eccentric exercise training in tendinopathy has been applied since the 1980s.¹ In 1996, Alfredson *et al*² showed that among 13 patients undergoing surgical treatment for chronic Achilles tendinopathy, 6 months of postoperative rehabilitation for chronic Achilles tendinitis was not enough to recover concentric and eccentric plantar flexion muscle strength compared with the non-injured side. In 1998, 15 recreational athletes with chronic Achilles tendinopathy performed a calf muscle strength training >12 weeks, with all 15 patients back at their preinjury levels with full running activity after the eccentric training regimen.³ Currently, mid-portion tendinopathy is believed to be superiorly reduced by eccentric training, with only limited effects in insertional tendinopathy.

Response rates to eccentric training vary, with highest rates reported among high-level athletes and lower response rates of about 60% among sedentary patients, as shown recently by Sayana and Maffulli.⁴ The effects of a 12-week eccentric training intervention on the pain level are evident about 6 weeks after initiation and last for at least 1 year.⁵ Among 25 patients, a decreased tendon thickness was noted for up to 3.8 years following a 12-week eccentric training intervention.⁶

It seems that the neovascularisation is decreased by an eccentric training intervention, as demonstrated by colour Doppler sonography.⁷ Recently an increased collagen synthesis rate with increased carboxy terminal propeptide of type I collagen (3.9 (2.5) µg/l before to 19.7 (5.4) µg/l after, $p<0.05$) using microdialysis technology was found after 12 weeks of eccentric training among six soccer players with Achilles tendinopathy.⁸

Despite the accumulating published data regarding its effectiveness and possible pathophysiological effects among patients with chronic Achilles tendinopathy, no data are currently available regarding any potential associated adverse effects to the Achilles tendon microcirculation following painful eccentric training.

Laser Doppler flowmetry shows that baseline Achilles tendon microcirculation in healthy athletes differs from patients with either insertional or mid-portion tendinopathy, where capillary blood flow is increased at the point of pain.⁹ We hypothesised that 12 weeks of eccentric training does not harm Achilles tendon microcirculatory parameters among patients with chronic Achilles tendinopathy.

METHODS

A total of 59 patients (>18 years) were included after informed consent to participate in the study was obtained. The diagnosis of Achilles tendinopathy was made if patients exerted pain at the tendon at rest or at exercise, either at the insertional zone at the calcaneus or in the mid-portion area of the Achilles tendon 2–6 cm proximal to the insertion associated with tenderness and swelling after conventional grey-scale ultrasound showing hypoechoic texture and tendon enlargement. All patients with insertional pain did not have any bony abnormality such as Haglund exostosis, spurs or fragments, but had pure tendon abnormalities with tendon enlargement at the insertion with hypoechoic texture in grey-scale ultrasound. Patients with prior Achilles tendon surgery were excluded. None of the patients included had any prior therapy by eccentric exercise training before the study. The daily eccentric training was performed with 3×15 repetitions per tendon per day (2 s each position) with straight knee only.

Mid-portion and insertional tendinopathy

The distribution was 49 patients with chronic mid-portion tendinopathy and 10 patients with chronic insertional

Abbreviation: FAOS, Foot and Ankle Outcome Score

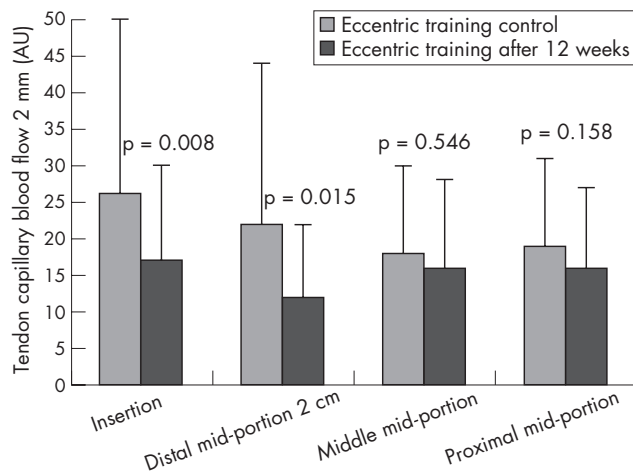


Figure 1 Achilles tendon capillary blood flow at 2 mm depth at baseline at the start of the study (left) and after (right) 12 weeks of daily painful eccentric training in chronic Achilles tendinopathy in 59 patients with 64 symptomatic tendons.

tendinopathy with a total number of 64 symptomatic Achilles tendons (54 mid-portion and 10 insertional with pure tendon problems without bony abnormalities).

Symptoms, function and foot and ankle-related quality of life were evaluated by the Foot and Ankle Outcome Score (FAOS). The FAOS has been found to have a high test-retest reliability, indicating that the FAOS is an accurate measure with high ability to measure even small changes over time.^{5–10} Pain was assessed on a Visual Analogue Scale, ranging from 0 for no pain at all to 10 for the most imaginable pain.

A non-invasive real-time combined laser Doppler and spectroscopy system (Oxygen-to-see, LEA Medizintechnik, Giessen, Germany) was applied, which has been used clinically as mentioned before in the Achilles tendon as well as in studying the effects of combined cryotherapy and compression (Aircast Cryo/Cuff, Summit, New Jersey, USA) at the ankle level.¹¹ The Oxygen-to-see system has been shown to have a high intraobserver and interobserver reliability.¹²

Every subject was measured at both legs at four positions, which were placed on the Achilles tendon. We determined the microcirculation at 2 and 8 mm tissue depths at each level at four tendon positions, which were exactly the same in each patient. All positions were determined in relation to the bony heel by measurement of length and were exactly the same on both legs in each patient:

- Insertion of the Achilles tendon
- 2 cm proximal of the insertion as distal mid-portion position
- 4 cm proximal of the insertion as middle mid-portion position
- 6 cm proximal of the insertion as proximal mid-portion position.

Statistics

The data are presented as median and range for continuous variables or number and percentages for dichotomous variables. Univariate analysis of categorical data was carried out using the χ^2 or Fisher exact tests. Student's t test was applied for parametric, ordinal variables of connected samples. A p value <0.05 was considered to indicate significance. SPSS V.13.0 for Windows was used for statistical analysis.

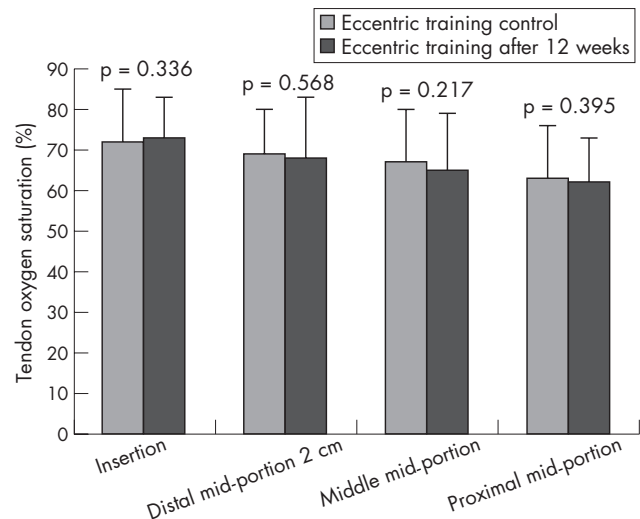


Figure 2 Achilles tendon oxygen saturation at the start of the study (left) and after (right) 12 weeks of daily painful eccentric training in chronic Achilles tendinopathy in 59 patients with 64 symptomatic tendons.

RESULTS

Tendon capillary blood flow

Achilles tendon capillary blood flow was significantly reduced at the insertion at 2 mm (by 35%, $p = 0.008$, fig 1) and at 8 mm tissue depth (98 (7) vs 76 (53), $p = 0.007$) in all patients with tendinopathies. Focusing only on the patients with insertional pure tendinopathies, insertional capillary blood flow was reduced superficially, not significantly, with only 10 tendons (24 (27) vs 15 (11), -37% , $p = 0.325$), an effect that was seen at the distal mid-portion (20 (31) vs 11 (10), -45% , $p = 0.112$) and the middle mid-portion (18 (11) vs 10 (9), -45% , $p = 0.169$) for insertional tendinopathy. At 8 mm tissue depth, in patients with insertional tendinopathy the capillary flow was reduced at the insertion (105 (81) vs 70 (48), -33% , $p = 0.173$), the distal mid-portion (93 (71) vs 65 (37), -30% , $p = 0.197$) and the middle mid-portion (83 (46) vs 53 (18), -36% ,

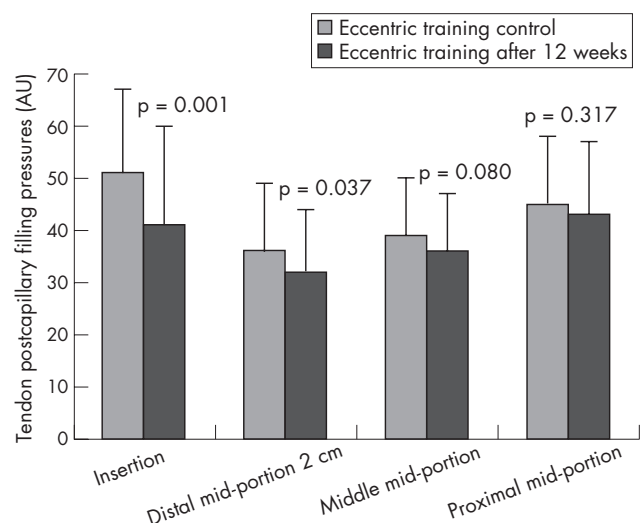


Figure 3 Achilles tendon postcapillary venous filling pressures at the start of the study (left) and after (right) 12 weeks of daily painful eccentric training in chronic Achilles tendinopathy in 59 patients with 64 symptomatic tendons.

Table 1 Patient characteristics among 59 patients with 64 symptomatic Achilles tendons

	Eccentric training, n = 59 patients with 64 tendons
Men	39 (61%)
Female	25 (39%)
Age (years)	49 (12)
Mid-portion	49 points with 54 tendons
Insertional (pure tendon problems, no bony abnormalities)	10 points with 10 tendons
Body mass index (kg/m ²)	27 (5)
<19.9	4 (6%)
20–24.9	18 (28%)
25–29.9	31 (48%)
30–34.9	6 (9%)
35–39.9	3 (5%)
>40	2 (3%)
Profession	
Physically demanding job	15 (23%)
Student	2 (3%)
Retired	8 (12.5%)
Teacher	7 (11%)
Academic	20 (31%)
Non-academic	35 (55%)
Training	
Healthy sports (walking, swimming, biking)	46 (72%)
Running	19 (30%)
Soccer	5 (8%)
All other ball sports	12 (19%)
Injuries	
Achilles tendon	9 (14%)
Previous plantar fasciitis	3 (6%)
Previous ankle sprain	16 (25%)
Knee	14 (22%)
Arthritis	6 (43%)
Meniscus tear	1 (7%)
Ligament injury	5 (36%)
Others	2 (14%)
Muscle injuries	5 (8%)
Ankle arthritis	9 (15%)
Injury at symptomatic tendon side	25 (40%)
History	
None	47 (76%)
Diabetes mellitus	4 (6%)
Arterial hypertension	16 (25%)
Smoking	
Never	57 (89%)
<5 cigarettes/day	1 (2%)
>5 cigarettes/day	6 (9%)

p = 0.085), not significantly, owing to the large standard deviation among the 10 insertional pain tendons. Furthermore, at the superficial distal mid-portion area, the tendon capillary blood flow was reduced significantly (22 (32) vs 12 (10), p = 0.015). At all other positions, the capillary blood flow was reduced, but did not reach any level of significance among the 59 patients included. No increase of capillary blood flow was noted.

Tendon oxygen saturation

Eccentric training does not compromise tendon oxygen saturation throughout the entire tendon. From the insertion (72 (13) vs 73 (10), p = 0.336, fig 2) to the proximal mid-portion area (63 (13) vs 62 (11), p = 0.395), no significant change was noted. Following division in insertional and mid-portion tendinopathy, no significant changes of tendon oxygen saturation were evident throughout the tendon.

Table 2 Postcapillary venous filling pressures among 49 patients with mid-portion tendinopathy with 54 symptomatic tendons

	2 mm	%	p Value	8 mm	%	p Value
Insertion	51 (16) vs 41 (18)	-20	0.003	64 (18) vs 53 (13)	-17	0.001
Distal mid-portion	36 (13) vs 32 (11)	-11	0.066	58 (21) vs 54 (19)	-7	0.253
Middle mid-portion	38 (11) vs 36 (11)	-5	0.273	54 (18) vs 51 (14)	-6	0.167
Proximal mid-portion	44 (14) vs 42 (13)	-5	0.282	60 (21) vs 57 (21)	-5	0.340

Table 3 Postcapillary venous filling pressures among 10 patients with insertional tendinopathy with 10 symptomatic tendons

	2 mm	%	p Value	8 mm	%	p Value
Insertion	49 (24) vs 39 (25)	-20	0.438	65 (26) vs 53 (18)	-18	0.149
Distal mid-portion	32 (8) vs 29 (16)	-9	0.437	54 (21) vs 55 (23)	2	0.899
Middle mid-portion	37 (10) vs 33 (10)	-11	0.312	54 (20) vs 48 (14)	-11	0.336
Proximal mid-portion	45 (16) vs 48 (14)	7	0.348	54 (19) vs 63 (27)	17	0.169

Tendon post-capillary venous filling pressures

Eccentric training decreases post-capillary venous filling pressures throughout the entire Achilles tendon with predominant effects at the tendon insertion at 2 mm (51 (16) vs 41 (19), $p=0.001$) and 8 mm tissue depths (63 (19) vs 51 (13), $p=0.0001$, fig 3). No increase in tendon post-capillary venous filling pressure was noted. Tables 1–3 show the differentiation for mid-portion and insertional tendinopathy.

Foot and Ankle Outcome Score

The eccentric training could significantly increase the FAOS regarding symptoms (93 (16) vs 94 (16), $p=0.01$), pain (98 (18) vs 99 (19), $p=0.023$), sport (95 (23) vs 97 (20), $p=0.002$) and quality of life (88 (17) vs 92 (24), $p=0.0001$).

Pain on Visual Analogue Scale

The eccentric training reduced the overall pain in Achilles tendinopathy significantly from 5.5 (2.1) to 3.6 (2.4; $p=0.0001$). At a follow-up of 12 months, no Achilles tendon rupture occurred. Pain was reduced from 5.4 (2.1) to 3.6 (2.4; $p=0.001$) in the mid-portion and from 6 (2.5) to 3.2 (2.7; $p=0.002$) in the insertional tendinopathy group (fig 4).

DISCUSSION

A 12-week eccentric training regimen is not harmful for altered Achilles tendon microcirculation in insertional and mid-portion Achilles tendinopathy. Increased tendon capillary blood flow is decreased significantly at the insertion and the distal mid-portion area in symptomatic tendons, which is in line with the published data regarding the disappearance of neovessels following eccentric training.^{6,7} Interestingly, patients with both mid-portion and insertional tendinopathy could reduce their pain level following 12 weeks of painful eccentric training. The patients with insertional pain included in this study had pure tendinopathy without any bony abnormality such as Haglund

exostosis or spurs, which might have caused impingement with limited success for the patients.

This paper shows for the first time that Achilles tendon oxygenation is not impaired by painful 12-week eccentric training throughout the entire symptomatic tendon. A decreased tissue oxygenation is associated with local acidosis and impaired cell function owing to relative ischaemia, as shown in case of vessel removal.¹³ An increased tendon oxygen saturation might enhance the local metabolism, which can be achieved by intermittent cryotherapy and compression using the Cryo/Cuff device (Aircast) on the mid-portion Achilles tendon¹⁴ or in case of preconditioning such as in cardiac surgery, to prepare the myocardium against ischaemia in beating heart surgery.

The post-capillary Achilles tendon venous filling pressures indicate the capillary outflow out of the tendon. Increased post-capillary tendon pressures cause venous congestion and deteriorate local metabolic function.¹⁵ This is encountered in disease states such as post-thrombotic syndromes. We found that decreased pressures after 12 weeks of eccentric training thus facilitate capillary venous outflow and are therefore beneficial for the local clearance of metabolic end products, which might decrease pain in addition to reduced capillary tendon blood flow. Eccentric training reduces post-capillary venous filling pressures throughout the tendon with maximal effects at the tendon insertion.

In conclusion, we found that 12-week eccentric training is not harmful with regard to the microcirculatory Achilles tendon level. It is beneficial, easy to apply and should be promoted broadly among patients with mid-portion as well as insertional tendinopathy without bony abnormalities, as the microcirculatory

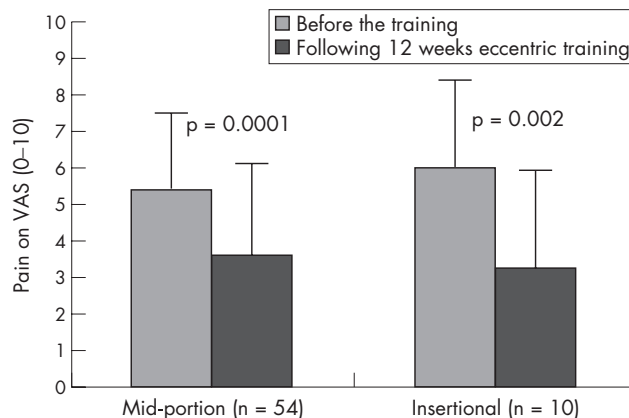


Figure 4 Pain on Visual Analogue Scale (VAS) for mid-portion tendinopathy (49 patients with 54 symptomatic tendons) and insertional tendinopathy (10 patients with 10 symptomatic tendons) after 12 weeks of daily eccentric training.

What is already known on this topic

- Neovascularisation plays an important role in Achilles tendinopathy. Capillary blood flow is quantitatively increased at the point of pain in both insertional and mid-portion Achilles tendinopathy.
- Daily painful eccentric training over 12 weeks can reduce pain in mid-portion tendinopathy.

What this study adds

- Daily painful eccentric training does not compromise insertional or mid-portion microcirculation.
- It is a safe and easy measure with beneficial effects on the microcirculatory tendon levels without any evident adverse effects in both mid-portion and insertional Achilles tendinopathy.
- Pain is reduced significantly in patients with mid-portion and pure insertional tendinopathy.

changes and the pain level reduction indicate that both groups may benefit from painful eccentric training.

Competing interests: None declared.

Correspondence to: Dr Karsten Knobloch, Sports Traumatology of the Hand and Wrist, Plastic, Hand and Reconstructive Surgery, Hannover Medical School, Carl-Neuberg-Str 1, 30625 Hannover, Germany; kknobi@yahoo.com

Accepted 24 October 2006

Published Online First 24 November 2006

REFERENCES

- 1 Stanish W, Rubinovich M, Curvin S. Eccentric exercise in chronic tendonitis. *Clin Orthop* 1986;**208**:65–8.
- 2 Alfredson H, Pietila T, Lorentzon R. Chronic Achilles tendinitis and calf muscle strength. *Am J Sports Med* 1996;**24**:829–33.
- 3 Alfredson H, Pietila T, Jonsson P, et al. Heavy-load eccentric calf muscle training for the treatment of chronic Achilles tendinosis. *Am J Sports Med* 1998;**26**:360–6.
- 4 Sayana MK, Maffulli N. Eccentric calf muscle training in non-athletic patients with Achilles tendinopathy. *J Sci Med Sport* 2007;**10**:52–8.
- 5 Roos EM, Engstrom M, Lagerquist A, et al. Clinical improvement after 6 weeks of eccentric exercise in patients with mid-portion Achilles tendinopathy—a randomized trial with 1-year follow-up. *Scand J Med Sci Sports* 2004;**14**:286–95.
- 6 Ohberg L, Lorentzon R, Alfredson H. Eccentric training in patients with chronic Achilles tendinosis: normalised tendon structure and decreased thickness at follow up. *Br J Sports Med* 2004;**38**:8–11.
- 7 Ohberg L, Alfredson H. Effects on neovascularisation behind the good results with eccentric training in chronic mid-portion Achilles tendinosis? *Knee Surg Sports Traumatol Arthrosc* 2004;**12**:465–70.
- 8 Langberg H, Ellingsgaard H, Madsen T, et al. Eccentric rehabilitation exercise increases peritendinous type I collagen synthesis in humans with Achilles tendinosis. *Scand J Med Sci Sports* 2007;**17**:61.
- 9 Knobloch K, Kraemer R, Lichtenberg A, et al. Achilles tendon and paratendon microcirculation in mid-portion and insertional tendinopathy in sportsmen. *Am J Sports Med* 2006;**34**:92–7.
- 10 Roos EM, Brandsson S, Karlsson J. Validation of the foot and ankle outcome score for ankle ligament reconstruction. *Foot Ankle Int* 2001;**22**:788–94.
- 11 Knobloch K, Kraemer R, Gössling T, et al. Microcirculation of the ankle after Cryo/Cuff application in healthy volunteers. *Int J Sport Med* 2006;**27**:250–5.
- 12 Ghazanfari M, Vogt L, Banzer W, et al. Reproducibility of non-invasive blood flow measurements using laser Doppler spectroscopy. *Phys Med Rehab Kuror* 2002;**12**:330–6.
- 13 Knobloch K, Lichtenberg A, Pichlmaier M, et al. Palmar microcirculation following harvesting of the radial artery in coronary revascularisation. *Ann Thorac Surg* 2004;**79**:1026–30.
- 14 Knobloch K, Grasmann R, Jagodzinski M, et al. Changes of Achilles mid-portion tendon microcirculation after repetitive simultaneous cryotherapy and compression using standardized cryo-compression device (Cryo/Cuff™). *Am J Sports Med* 2006;**34**:1953–9.
- 15 Knobloch K, Lichtenberg A, Pichlmaier M, et al. Sternal microcirculation after harvesting of the left internal thoracic artery in cardiac surgery. *Thorac Cardiovasc Surg* 2003;**51**:255–9.

COMMENTARY

The background to the good clinical effects of eccentric training on chronic midportion Achilles tendinosis is not clearly understood. This short report demonstrates the beneficial effects of eccentric training on microcirculation. The results of this study will most likely help to better understand the mechanisms behind the good effects on pain and tendon structure that have been previously demonstrated using this type of treatment model.

Hakan Alfredson

Department of Surgical and Perioperative Science, Umea University, Umea, Sweden; hakan.alfredson@idrott.umu.se